

# Thyroid gland tumor

A 42 year old woman noticed a growth in her neck that has been growing steadily for 3 months.

Dr Kevin Soh

Senior Consultant, Ear Nose & Throat Partners

Mt Elizabeth Medical Center #07-02

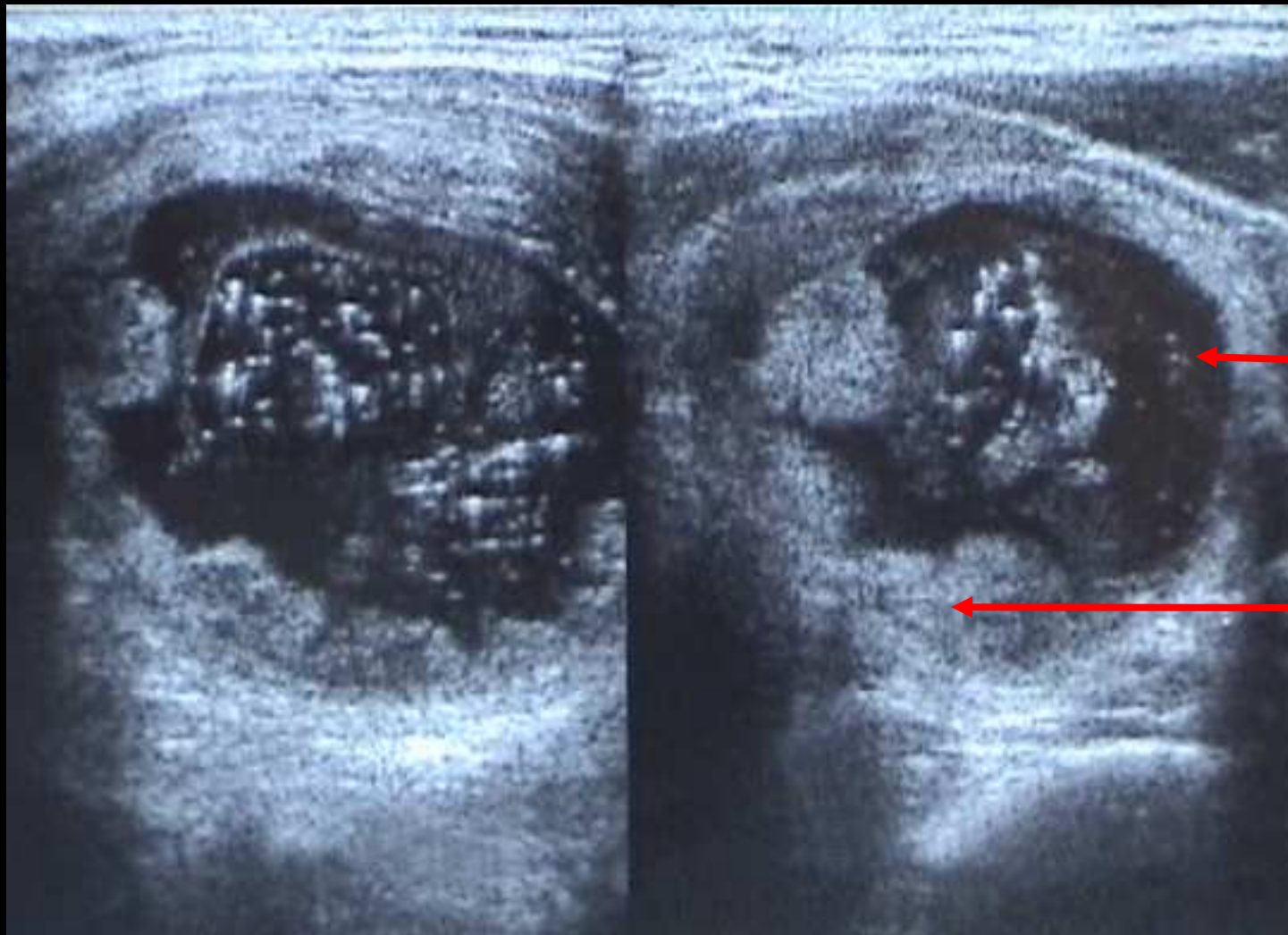
3 Mt Elizabeth, Singapore 228510

Tel: 65-6887-4385 or 9093-3584

Email: [kevinsoh@singnet.com.sg](mailto:kevinsoh@singnet.com.sg)

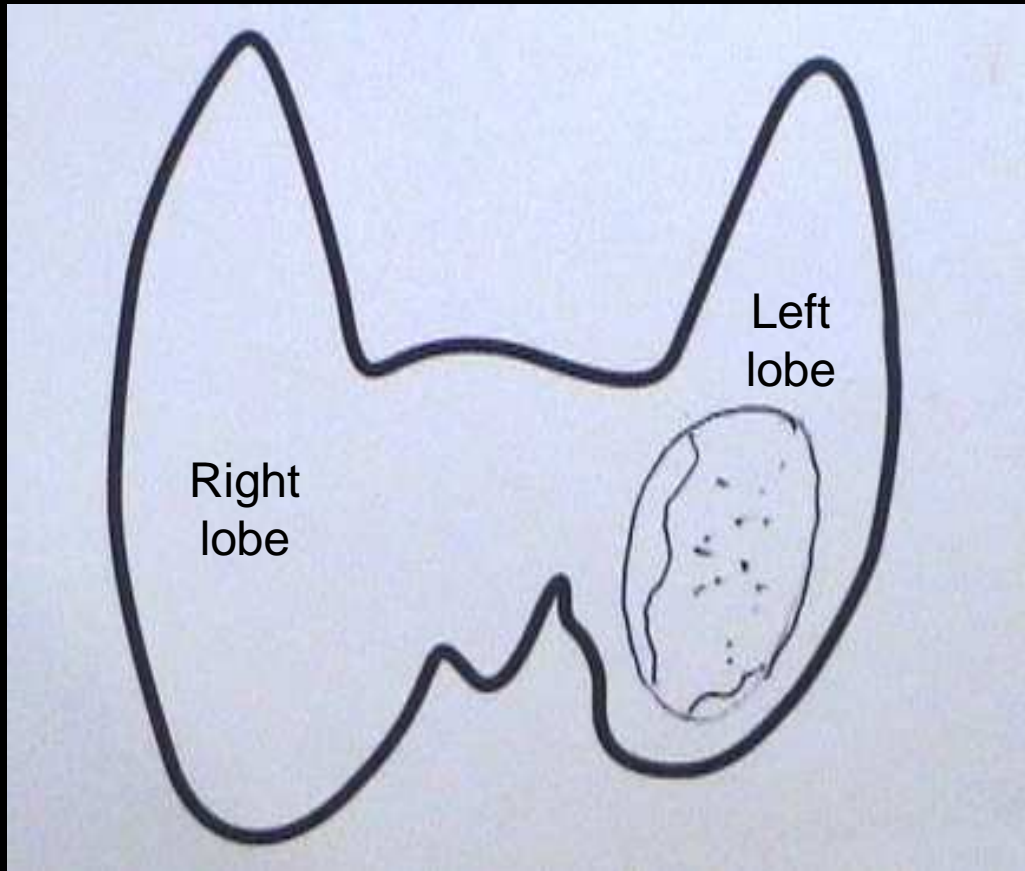
Web page: <http://www.NoseSinus.com>

Ultrasound thyroid scan shows a left thyroid mass that is mixed, i.e. containing both cystic and solid components.



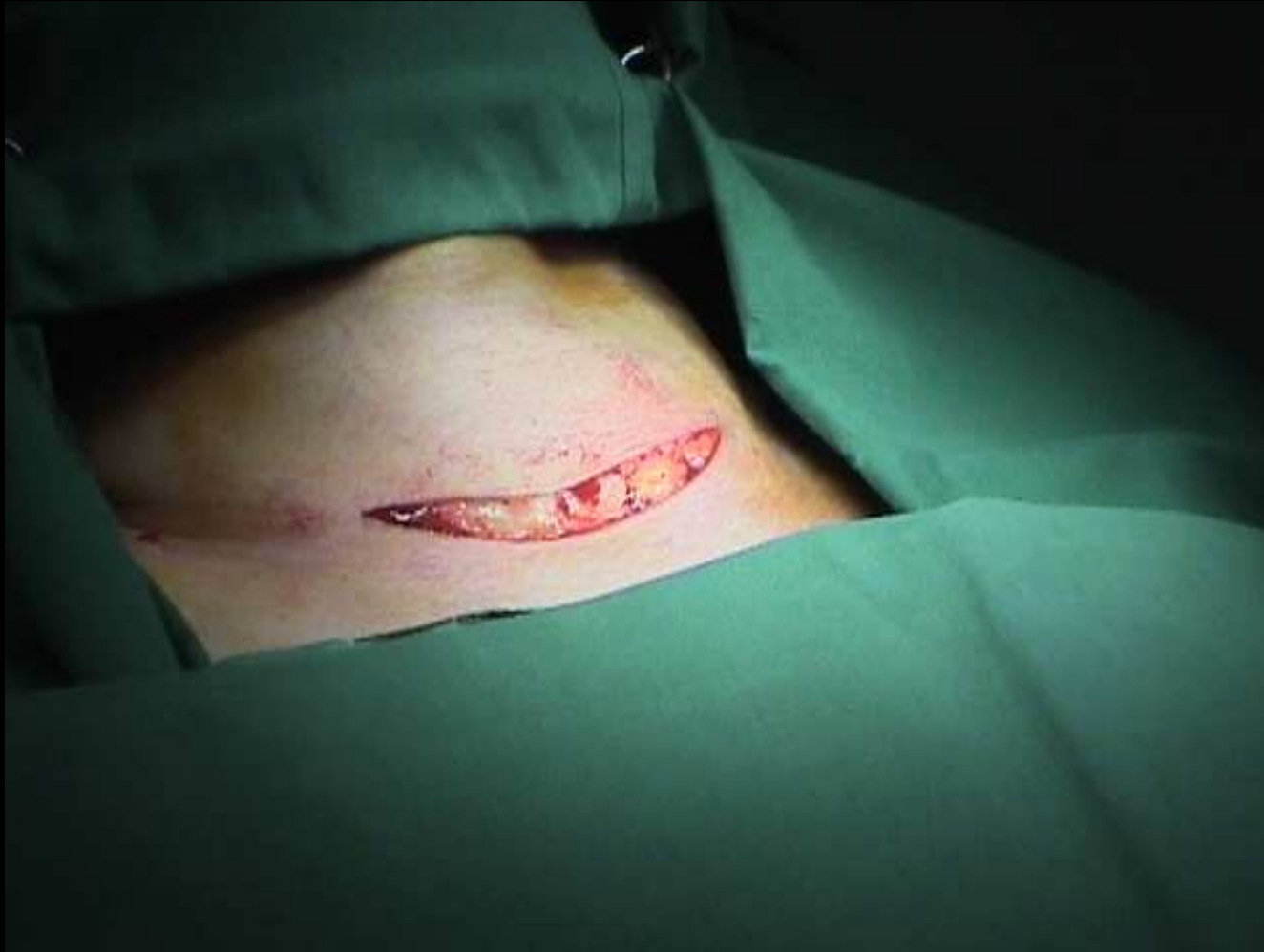Cystic component

Solid component



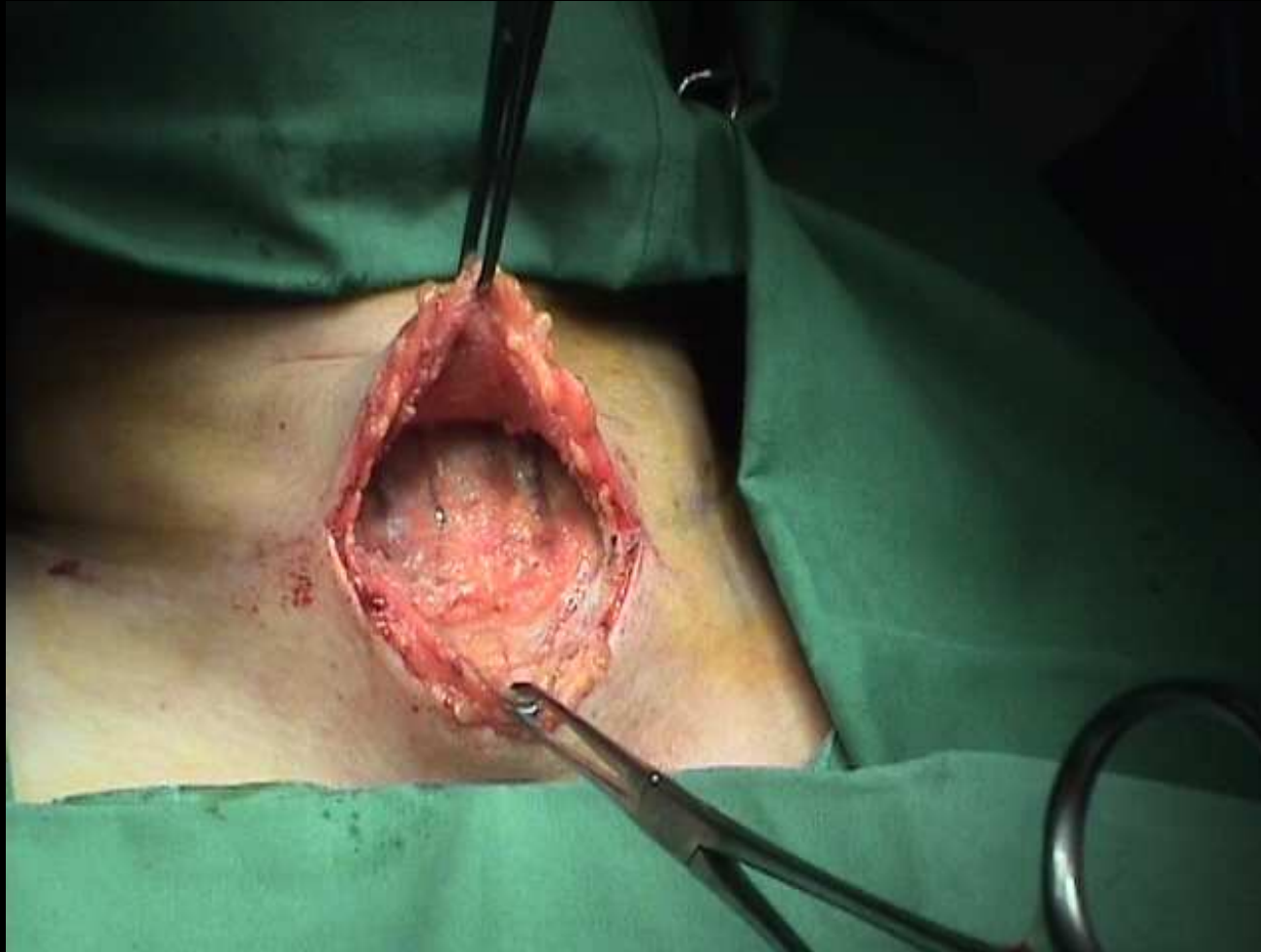
### Thyroid ultrasound scan report:

- ✓ Mixed left thyroid mass measuring 4.1 cm in diameter with cystic and solid components identified.
- ✓ No calcification seen.
- ✓ The mass is solitary and is not a part of multinodular thyroid disease.
- ✓ Normal right thyroid gland.
- ✓ No cervical lymph node enlargement.



Horizontal incision made along a skin crease low in the neck.

When the wound heals, the scar will become nearly invisible.



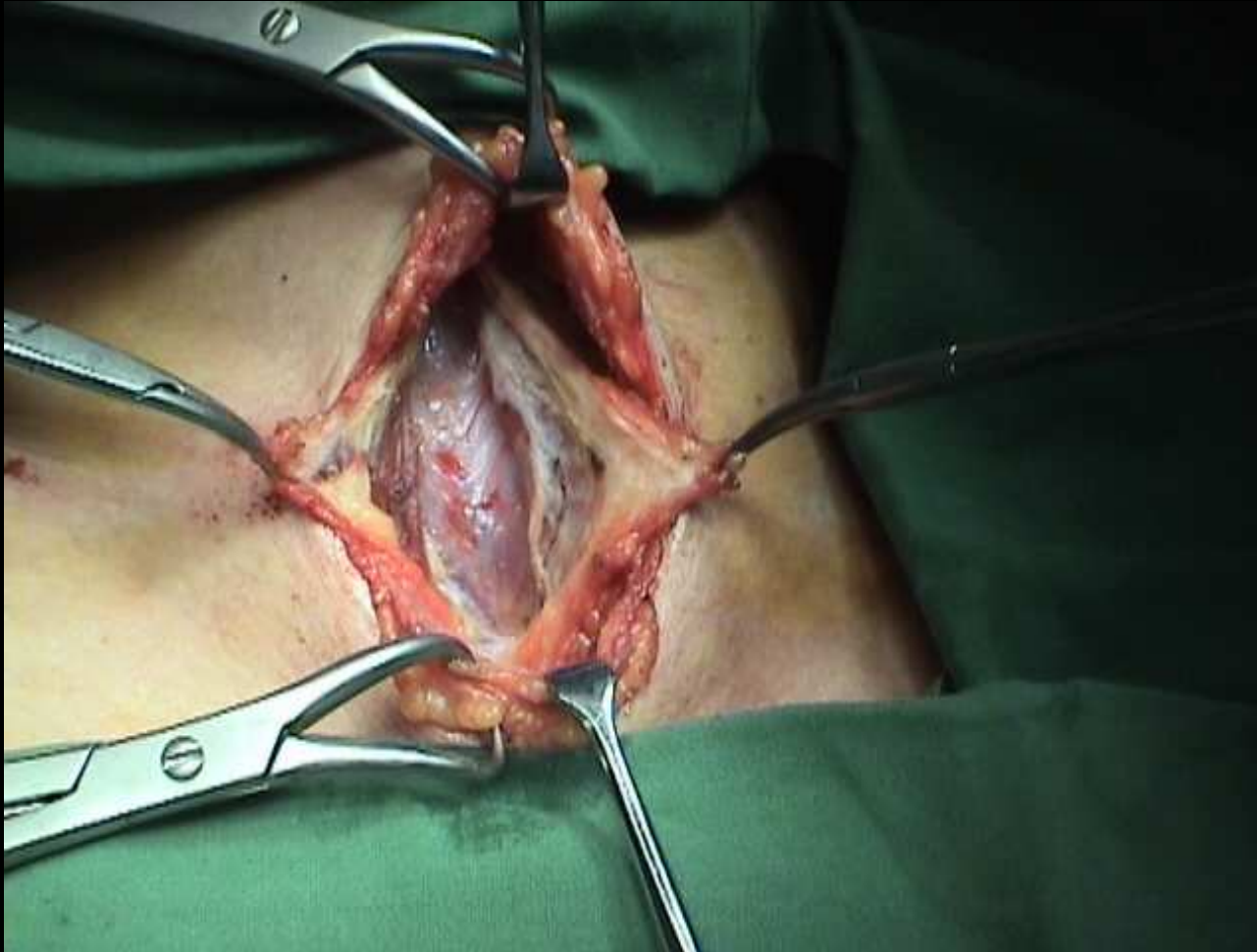Skin flaps are raised in the sub-platysmal plane, i.e. deep to the platysma muscle.

Surgery must be bloodless & dry in order to facilitate good visualization of the tissues.

The skin flap has to reach the larynx above, and the sternal notch below.

Notice the anterior jugular veins in the operative field.

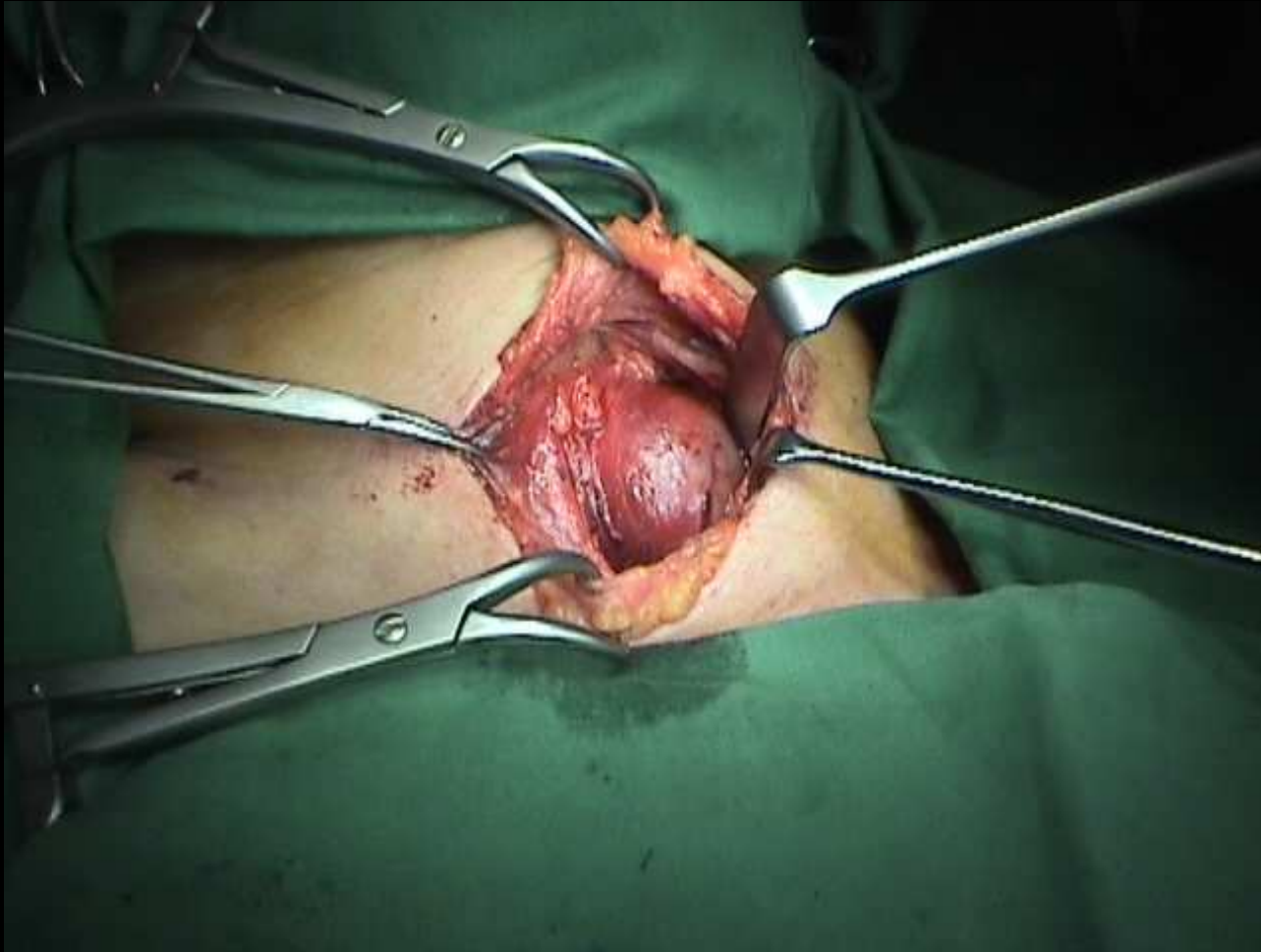




The strap muscles are separated longitudinally to expose the thyroid gland.

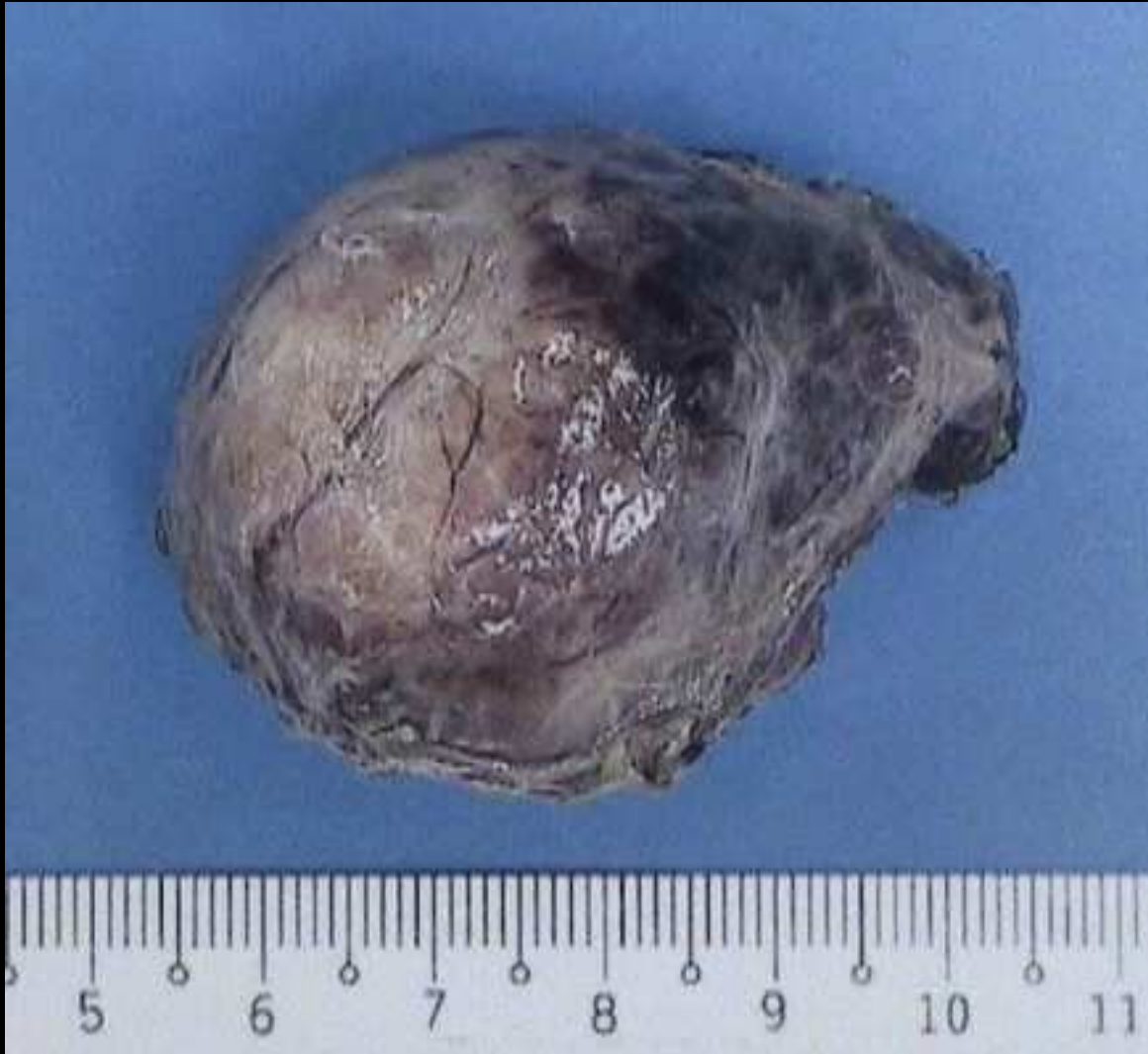Blood vessels must be preserved to avoid unnecessary bleeding.

Good surgery must be clean, dry, and bloodless.



The left thyroid mass is exposed.

It is carefully dissected out without injuring the recurrent laryngeal nerve, parathyroid glands, and blood vessels.



The thyroid mass specimen measuring 4.5 cm in diameter is sent to the laboratory for microscopic analysis.